

Aligner Treatment in the Teenage Patient

ORHAN TUNCAY, DMD
S. JAY BOWMAN, DDS, MSD
BRIAN AMY, DDS
JONATHAN NICOZISIS, DMD

Orthodontic therapy with fixed appliances has certain inherent drawbacks, including increased oral bacteria and microflora,¹⁻⁵ dental and soft-tissue discomfort, and poor esthetics. Teenage patients may be particularly reluctant to undergo fixed-appliance treatment for social reasons, but doctors and parents have been skeptical about their willingness to cooperate with removable clear aligners.

To alleviate these concerns, Invisalign Teen* aligners incorporate three features specifically for adolescents: wear-compliance indicators,⁶ Power Ridges for lingual root torque, and eruption compensation to accommodate naturally erupting canines, second premolars, and second molars.

A recent study comparing the periodontal status of adult patients after 12 months of treatment with fixed appliances vs. removable aligners found diminished periodontal status and increased levels of periodontopathic bacteria with the fixed appli-

ances.⁷ Because clinical experiences of teenage patients with aligners had not previously been investigated, however, we designed a study to evaluate three aspects of treatment with Invisalign Teen in our own private practices. An analysis of the effectiveness of wear-compliance indicators has already been published⁶; the present article summarizes our results in the remaining two areas of study: patient oral health and patient satisfaction.**

Materials and Methods

This prospective clinical study involved patients in four practices, located in Michigan, New Jersey, Oklahoma, and Pennsylvania. All study protocols were approved by the RCRC Independent

*Registered trademark of Align Technology, Inc., San Jose, CA; www.invisalign.com.

**Additional data tables are accessible from the electronic version of this article in the Online Archive at www.jco-online.com.



Dr. Tuncay



Dr. Bowman



Dr. Amy



Dr. Nicozisis

Dr. Tuncay is Professor, Chairman, and Director of the Graduate Program and Dr. Amy is a Clinical Assistant Professor, Department of Orthodontics, Kornberg School of Dentistry, Temple University, 3223 N. Broad St., Philadelphia, PA 19140. Dr. Amy is also in the private practice of orthodontics in Oklahoma City. Dr. Bowman is a Contributing Editor of the *Journal of Clinical Orthodontics* and in the private practice of orthodontics in Portage, MI; he is also an Adjunct Associate Professor at St. Louis University and a straight-wire instructor at the University of Michigan. Dr. Nicozisis is in the private practice of orthodontics in Princeton, NJ. E-mail Dr. Tuncay at otuncay@dental.temple.edu.

Review Board in Austin, Texas. Subjects were chosen without regard to gender from among non-extraction patients diagnosed as having Class I or mild Class II occlusions. Exclusions were made for active caries, periodontal disease, and any conditions that are considered inappropriate for treatment with aligners. At the start of the study, all 62 qualified patients were 18 years old or younger, and all subjects' deciduous teeth had exfoliated.

The investigation was launched in December 2007, and patient recruitment closed in January 2009. Parents were given a fee discount of about 20% for participation in the study, and patients were rewarded with gift certificates for each study-related visit involving records and data collection.

Treatment was planned and executed by the respective clinicians, but the aligners were prescribed to be worn about 21 hours per day. All aligners were outfitted with wear-compliance indicators,⁶ and 49 of the original 62 patients required Power Ridges for lower anterior torque control. Total treatment times ranged from eight to 42 months, although study data were not collected after the first 24 months.

Each patient's plaque, gingival-bleeding, and decalcification scores were recorded by the treating orthodontist, using plaque and gingival-bleeding indices adopted from a study by the University of Florida.⁸ Scores were recorded at the initial treatment appointment, at each subsequent visit (every three months), and at the end of treatment (or after 24 months). In addition, quality-of-life questions about physical and social comfort were asked every three months as a measurement of patient satisfaction. The participating orthodontists completed a survey about ease of treatment and chairtime requirements for each patient at the first three-month visit and the final appointment.

Results

Of the 62 patients who began the study, 42 completed treatment. Reasons for withdrawal included early poor cooperation with aligner wear, failure to return regularly for data collection, and decisions to terminate treatment. Male and female patients were equally compliant.

The use of aligners did not affect the length of orthodontic treatment in this study population. The average number of case refinements was between one and two per patient, which is fairly normal in our experience. Treating teenagers with aligners was mostly reported to be "easy" or "very easy". Also advantageous was an average chairtime per visit of 3.5 minutes for the doctor and 10.5 minutes for staff.

Oral Health

Between initial and final data collection, the plaque index showed an average reduction of 15.1% in the maxilla and 16.6% in the mandible (Fig. 1), although the difference was not statistically significant for the mandible. The highest average scores at both the beginning and end of treatment were recorded for the maxillary molars, where plaque still covered less than one-third of the enamel surface. All other teeth exhibited, on average, only a minimal (≤ 1 mm) band of plaque.

According to the gingival-index measurements, all patients exhibited less than slight papillary bleeding throughout treatment (Fig. 2).

Although the average plaque index increased slightly at three months (.1 higher than at the start of treatment), there was either no difference or a slight decrease at every interval thereafter ($p < .02$). The average gingival index, on the other hand, showed a modest increase following the third month of treatment ($p < .0005$), but the fluctuations were no more than .2 on a five-point scale, indicating minimal clinical significance. On the whole, the plaque and gingival indices demonstrated significantly better oral conditions than those reported for orthodontic patients wearing fixed appliances.^{9,10}

Decalcification indices were recorded for a total of 336 teeth (Fig. 3). Only three teeth (.9%) showed an increase of two points each on the scale, while another three teeth changed by three points each. The majority of teeth exhibited no change (75.6%) or a one-point increase (14.3%). Enamel lesions were virtually nonexistent. These findings are significantly more favorable than those of Chapman and colleagues, who reported at least

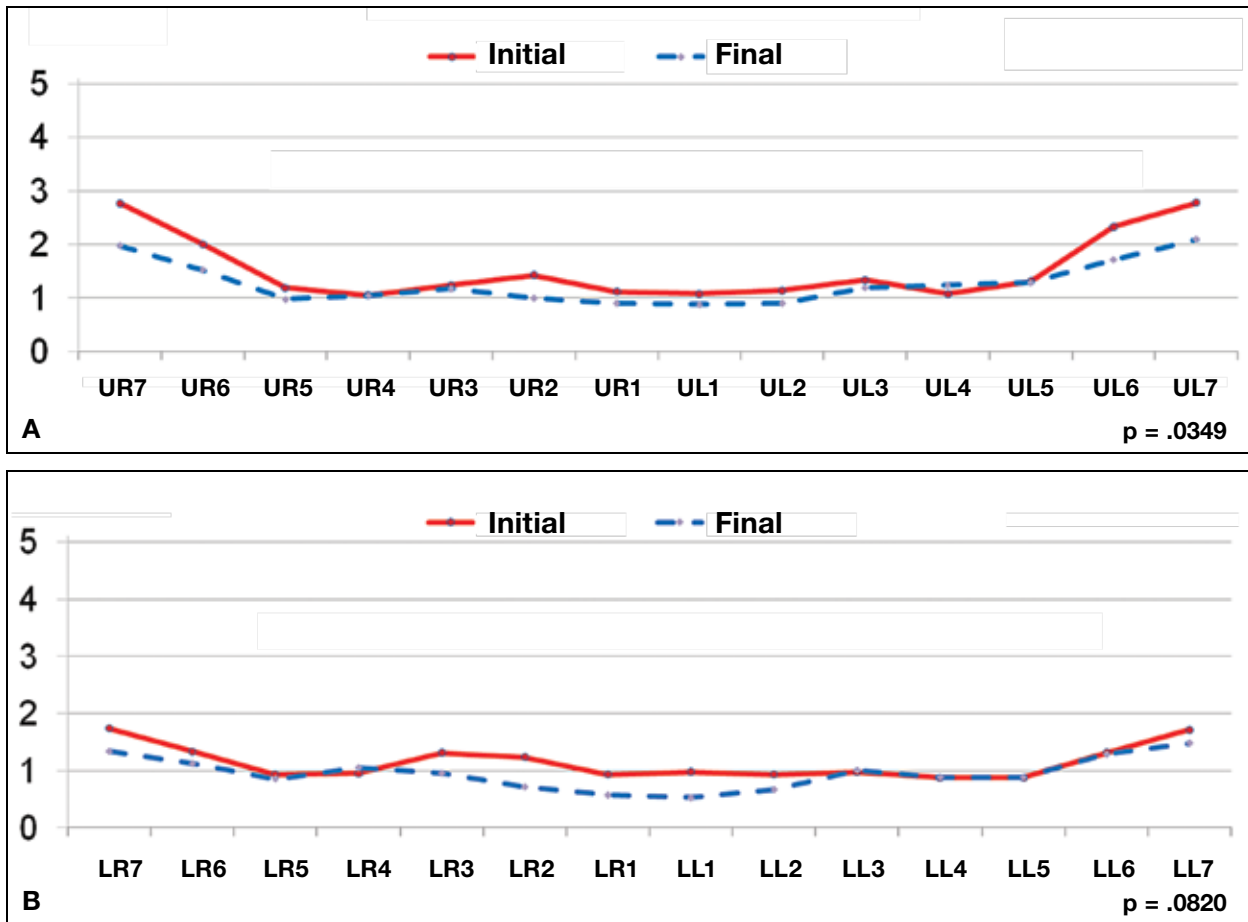


Fig. 1 Maxillary (A) and mandibular (B) plaque indices⁸: 0 = no plaque visible; 1 = separate flecks of plaque visible at gingival margin; 2 = thin, continuous band of plaque (≤ 1 mm) at gingival margin; 3 = band of plaque wider than 1mm but covering less than one-third of tooth surface; 4 = plaque covering between one-third and two-thirds of tooth surface; 5 = plaque covering more than two-thirds of tooth surface.

one white-spot lesion on the maxillary anterior teeth (including the incisors, canines, and first premolars) in every fixed-appliance patient.¹¹

Patient Satisfaction

The vast majority of patients either “seldom” or “never” limited the foods they ate, avoided contact or communication with others, or felt self-conscious while wearing their aligners. At the three-month visit, about 70% had “seldom” or “never” experienced discomfort from the aligners, and about 80% had “seldom” or “never” used pain relievers. As treatment progressed, the patients reported even less discomfort or other concerns.

Discussion

The results of this study indicate that aligner treatment does not adversely affect the oral health of the teenage patient. Although slightly increased plaque indices were observed around the maxillary molars, it is not uncommon to see more plaque accumulation on the posterior teeth than on the anterior teeth. A recent study of orthodontic patients wearing fixed appliances reported average plaque coverage of 57% in the anterior gingival region.¹⁰ This percentage would correspond to our plaque index of 4, whereas the worst average score recorded anywhere in the mouth in our study was less than 2. The same investigators reported 68%

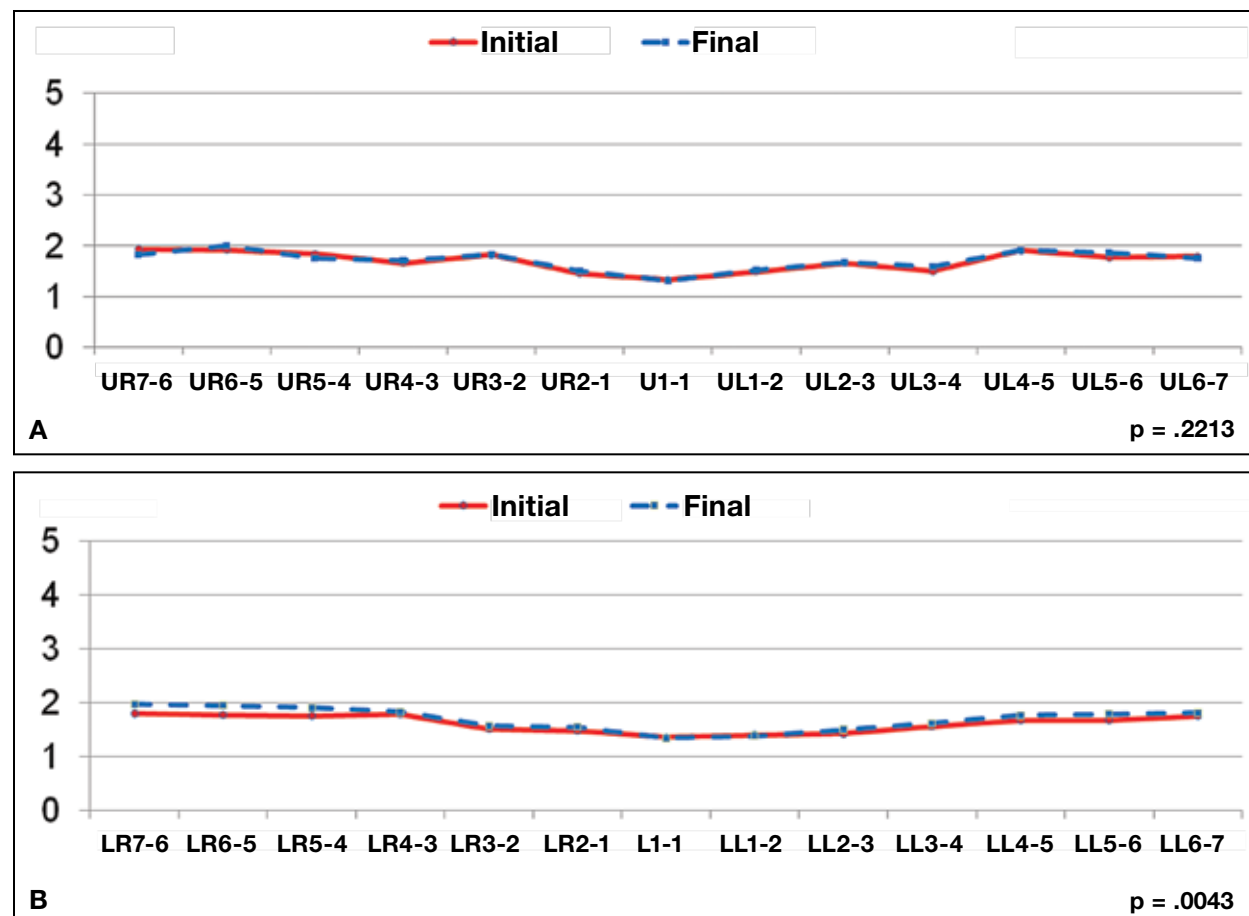


Fig. 2 Maxillary (A) and mandibular (B) gingival-bleeding indices⁸: 1 = no bleeding; 2 = slight bleeding; 3 = bleeding with flow; 4 = intermediate (copious) bleeding; 5 = spontaneous bleeding.

plaque coverage around orthodontic brackets; although this is a non-issue for Invisalign patients, it is important to note that even without bonded brackets, teenagers may accumulate plaque and experience mild papillary bleeding. Anecdotally, it seemed to us that the areas near the gingival margins were more difficult to brush for some teenage patients.

Conclusion

The teenagers who stayed enrolled in this study had no difficulty in compliance and were satisfied with their aligner treatment, indicating a

potential opportunity to treat young patients who might not otherwise accept orthodontic care. In addition, our results showed favorable consequences for periodontal health compared to fixed-appliance treatment.

ACKNOWLEDGMENTS: This study was supported by a research grant from Align Technology, Inc. The authors are grateful for the assistance of Ms. Sherri Wilson in the preparation of this manuscript.

REFERENCES

1. Boyd, R.L. and Baumrind, S.: Periodontal considerations in the use of bonds or bands on molars in adolescents and adults, *Angle Orthod.* 62:117-126, 1992.
2. Hägg, U.; Kaveewatcharanont, P.; Samaranayake, Y.H.; and

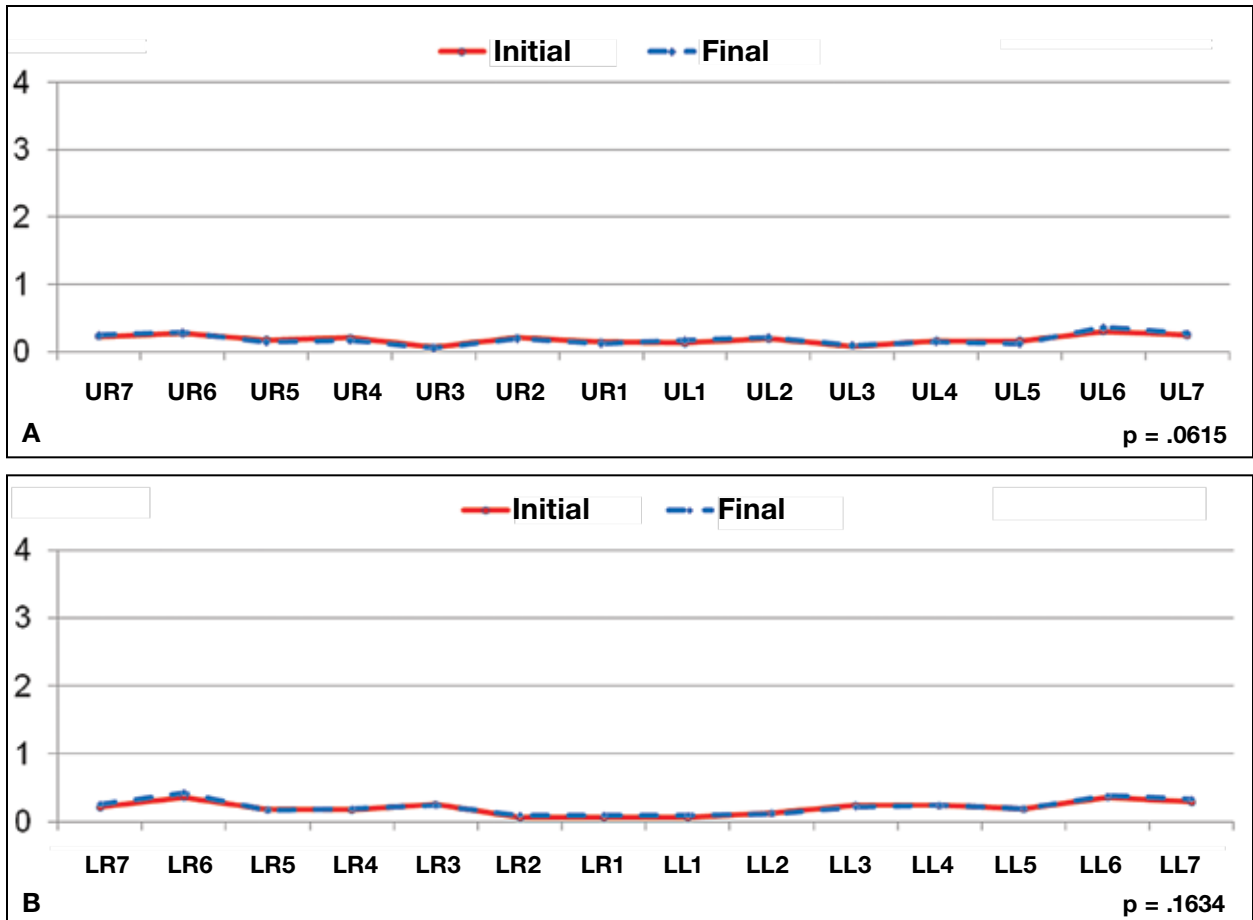


Fig. 3 Maxillary (A) and mandibular (B) decalcification indices: 0 = no white spots present; 1 = visible white spots without surface interruption (mild); 2 = visible white spots with roughened surface but requiring no restoration (moderate); 3 = visible white spot lesion with surface interruption (severe); 4 = cavity (cavitation).

- Samaranayake, L.P.: The effect of fixed orthodontic appliances on the oral carriage of *Candida* species and *Enterobacteriaceae*, *Eur. J. Orthod.* 26:623-629, 2004.
3. Gong, X.; Chen, W.; Gong, Y.; and Zhou, L.: [Clinical analysis of PLI, GI and SBI in patients with fixed orthodontic appliances], *Shanghai Kou Qiang Yi Xue* 15:367-369, 2006.
 4. Zhao, H.; Xie, Y.; and Meng, H.: [Effect of fixed appliance on periodontal status of patients with malocclusion], *Zhonghua Kou Qiang Yi Xue Za Zhi* 35:286-288, 2000.
 5. Leung, N.M.; Chen, R.; and Rudney, J.D.: Oral bacteria in plaque and invading buccal cells of young orthodontic patients, *Am. J. Orthod.* 130:698.e11-8, 2006.
 6. Tuncay, O.C.; Bowman, S.J.; Nicozisis, J.L.; and Amy, B.D.: Effectiveness of a compliance indicator for clear aligners, *J. Clin. Orthod.* 43:263-268, 2009.
 7. Karkhaneechi, M.; Chow, D.; Sipkin, J.; Sherman, D.; Boylan, R.J.; Norman, R.G.; Craig, R.G.; and Cisneros, G.J.: Periodontal status of adult patients treated with fixed buccal appliances and removable aligners over one year of active orthodontic therapy, *Angle Orthod.* 83:146-151, 2013.
 8. Taylor, M.G.; McGorray, S.P.; Durrett, S.; Pavlow, S.; Downey, N.; Lenk, M.; Oxford, E.; Dolce, C.; and Wheeler, T.T.: Effect of Invisalign aligners on periodontal tissues, *J. Dent. Res.* 82(Spec. Issue A):1483, 2003.
 9. Zachrisson, S. and Zachrisson, B.U.: Gingival condition associated with orthodontic treatment, *Angle Orthod.* 42:26-34, 1972.
 10. Klukowska, M.; Bader, A.; Erbe, C.; Bellamy, P.; White, D.J.; Anastasia, M.K.; and Wehrbein, H.: Plaque levels of patients with fixed orthodontic appliances measured by digital plaque image analysis, *Am. J. Orthod.* 139:e463-470, 2011.
 11. Chapman, J.A.; Roberts, W.E.; Eckert, G.J.; Kula, K.S.; and Gonzales-Cabezas, C.: Risk factors for incidence and severity of white lesions during treatment with fixed orthodontic appliances, *Am. J. Orthod.* 138:188-194, 2010.