

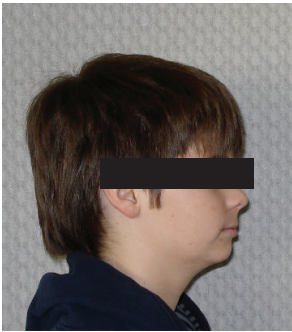# WHITEPAPER

---


## **Align Technology Case Report**

Dr. Jonathan Nicozisis, DMD, MS Princeton, NJ

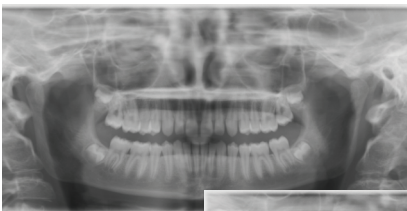
## CASE REPORT



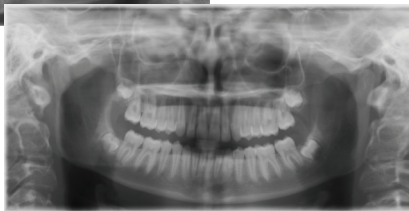
Before



A 13-year-old male presented with a Class 1 occlusion with 90% overbite and excessive spacing in the anterior teeth of both arches. There was more spacing in the upper arch, as teeth numbers 7 and 10 were slightly narrow in width. There was an excessive Curve of Spee in the lower arch, partially lending to the deep overbite. The patient had a Class 1 skeletal pattern with a lower-than-average mandibular plane angle. The upper and lower incisor inclinations were within normal limits. The panoramic radiograph showed normal dental development with third molars present.




Before



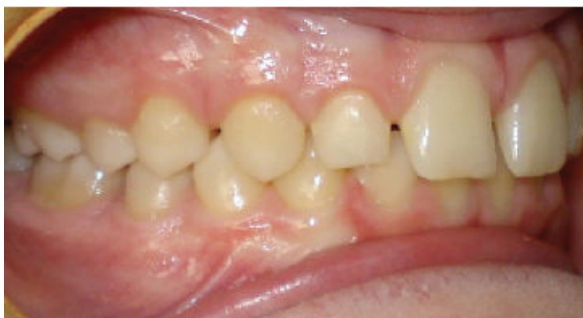After

The orthodontic treatment goals included closing the spaces in both arches and positioning the upper laterals for post-orthodontic restorative bonding and possible gingival recontouring if needed. Overbite correction was to be achieved via leveling of the Curve of Spee by extruding the lower bicuspid and intruding the anterior teeth. Closure of the upper anterior space would be achieved by applying lingual root torque during space closure to avoid excessive lingual tipping that could cause anterior interferences upon biting.

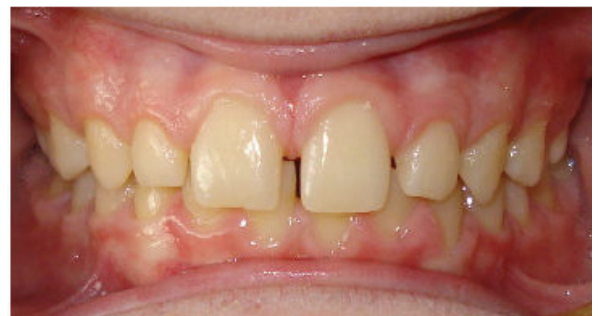

Power Ridges™

Power Ridge features were built into the aligners for teeth numbers 7, 8, 9, and 10 in order to apply a torquing moment during space closure. Attachments that were used on the lower bicuspid were designed to create a contrasting angle to the lingually inclined clinical crown. They have a broad surface that is as perpendicular as possible to the force acting on it, in this case extrusion, or pushing the tooth up.



Before

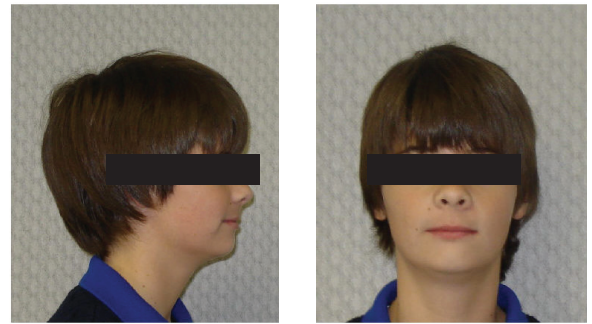

## RESULTS

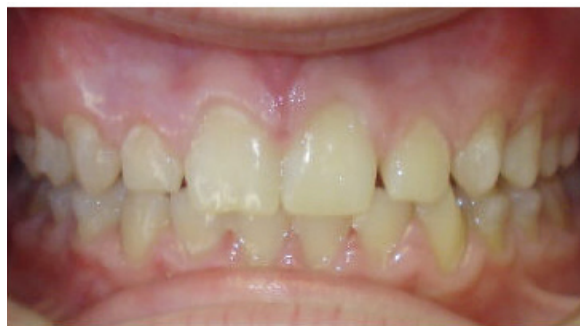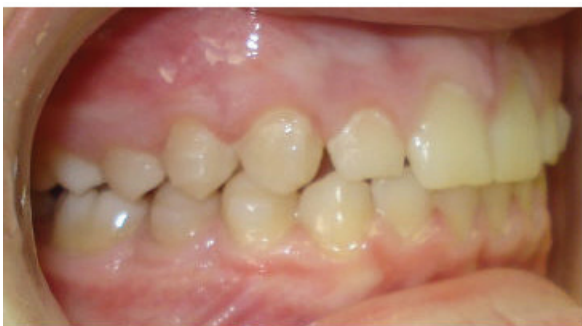---

In this case, there were eighteen aligners prescribed in each arch for a total of nine months of treatment. Treatment was completed without additional refinement aligners. Retention was accomplished with a fixed lingual bonded retainer for the maxillary centrals in addition to Essix-type retainers on both arches. Once the patient has his narrow maxillary lateral incisors bonded, a new upper retainer will be fabricated.

Post-treatment radiographs show excellent root parallelism. Incisal inclinations appear similar to the pre-treatment angles, thus showing an effective treatment plan approved in the ClinCheck® set-up. The aligner's Power Ridges were successful in maintaining the torque of the upper anterior teeth during space closure, while simultaneously correcting the overbite. Post-treatment study models clearly show successful leveling of the lower Curve of Spee as evidenced by the changes in the marginal ridges of the extruded lower premolars relative to their adjacent teeth. Patient compliance was excellent, and was easily monitored using the compliance indicators built into each of the upper Invisalign Teen aligners. Patient hygiene was also excellent, as can be readily seen by the absence of gingival inflammation and the absence of enamel decalcification after orthodontic treatment.



After



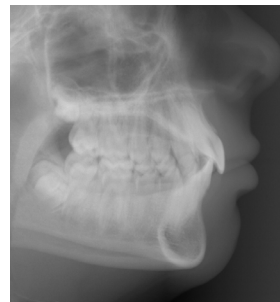After

## DISCUSSION

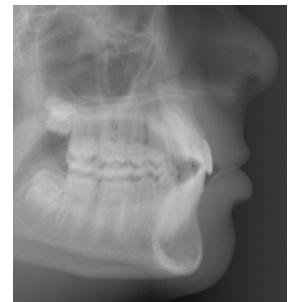One of the advantages of treating this patient using Invisalign Teen when compared to fixed orthodontic appliances was the ability it afforded to begin treatment in both arches simultaneously, despite the presence of the deep bite. This is the main reason why the case finished so quickly. Based on the initial deep overbite, it would have been nearly impossible to place lower fixed appliances during the first several months of treatment until some overbite correction was first accomplished in the upper arch. Fixed-appliance treatment would probably have taken four to five months longer, simply for the reason of not being able to bond appliances the lower arch at the onset. Some doctors might bond fixed bite-opening devices to the lingual surfaces of the upper incisors to help overcome this problem. This approach, however, can lead to other challenges, including breakage and reduced patient comfort from the inability of the patient to fully close down.

The presence of the aligner Power Ridges in this case was important for maintaining the torque of the upper four incisors during space closure. Despite the short clinical crowns of the maxillary laterals, the Power-Ridges proved effective in delivering the moment-to-force ratio needed to keep the teeth tracking within the aligners while delivering torquing vectors of force to these teeth.

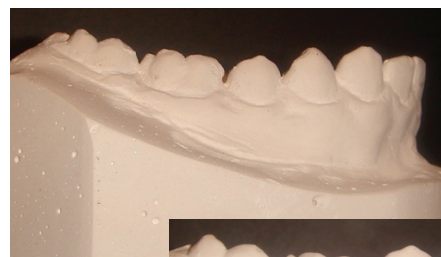
Finally, this case shows the ability to level a lower Curve of Spee with aligners in an adolescent patient with short clinical crowns. Curve of Spee Leveling was accomplished via extrusion of the lower buccal segments and intrusion of the lower anterior teeth. The dental extrusion in the lower arch was designed to be pure extrusion using attachments previously described in Clinical Reports and Techniques, 2006, as well as in my National Invisalign Summit presentations. My preferred attachment design is one where the attachments are beveled to create a better aligner/attachment interaction for the pushing forces being applied. In short, as the clinical crown tapers in the occlusal third, an attachment thicker at the occlusal margin tapering toward the gingival margin creates an undercut via a contrasting angle to the clinical crown that helps the aligner better grip the target tooth and effect the desired tooth movement. Using the Invisalign Teen product and its unique aligner features, the treatment of this teen patient was efficient, hygienic, and effective. The fact that the appliances were also extremely aesthetic and comfortable were added bonuses to this patient's positive treatment experience.



Before



After



Before



After

**invisalign** | *teen*

Align Technology, Inc.  
881 Martin Avenue • Santa Clara, CA 95050  
Tel: 408-470-1000 • Fax: 408-470-1010 • [www.aligntech.com](http://www.aligntech.com)

MOO115 Rev 1

Invisalign, and ClinCheck, among others are registered trademarks of Align Technology, Inc.